

The Spectrum of Antineutrophil Cytoplasmic Antibody (ANCA)-Associated Vasculitis:

DISEASE FUNDAMENTALS AND MANAGEMENT PATHWAYS

Curry L. Koenig, MD, MS, *Division of Rheumatology, University of Utah, and George E. Wahlen Department of Veterans Affairs Medical Center, Salt Lake City, Utah*

Irene von Hennigs, PharmD, *Vice President, Medical Affairs, ChemoCentryx, Inc., San Carlos, California*

OVERVIEW

The antineutrophil cytoplasmic antibody (ANCA)-associated vasculitides (ANCA vasculitis) are a group of rare, life-threatening autoimmune disorders that are marked by a necrotizing inflammatory process predominantly affecting small and medium-sized blood vessels.¹ The inflammatory processes underlying ANCA vasculitis can have severe clinical consequences; in particular, blood vessel rupture and/or occlusion and glomerulonephritis results in a number of organ-threatening—and often life-threatening—clinical manifestations.² ANCA vasculitis is a systemic disease with respiratory, renal, cardiovascular, neurologic, cutaneous, gastrointestinal, and ocular manifestations that occur with varying frequency depending on the subtype.³

Prompt diagnosis and aggressive management of ANCA vasculitis are important for preventing irreversible and often life-threatening organ damage and for reducing the high mortality associated with the disease. Unfortunately, the symptoms of ANCA vasculitis are easily confused with those of other diseases, often resulting in substantial diagnostic delays. Some case series suggest that up to a third of patients with ANCA vasculitis remain undiagnosed for at least 6 months after symptom onset, and a quarter of patients remain undiagnosed for a year or more.^{2,4} Left untreated, only 10% of patients with ANCA vasculitis will survive for more than 2 years.⁵ Among patients who are diagnosed and treated promptly, outcomes are much improved. Remission rates of 60% to 90% are observed, and more than 90% survive for more than 2 years after diagnosis.²

In general, most patients are treated in 2 phases: an initial, aggressive phase intended to rapidly induce remission and a longer-term maintenance phase. The management of ANCA vasculitis is intensive, complex, and of long duration, and it can be associated with significant toxicities that contribute to the already significant morbidity and mortality associated with this disease.

Optimal management of ANCA vasculitis requires coordinated multidisciplinary care because of the breadth of organ

systems involved and the complexity of treatment. This article will first discuss the definitions, classification, and epidemiology of ANCA-associated vasculitis and then turn to the pathophysiology and clinical manifestations of the disease. Finally, current and future management strategies will be examined.

HOW IS ANCA-ASSOCIATED VASCULITIS DEFINED AND CLASSIFIED?

The ANCA-associated vasculitides are defined as necrotizing inflammatory disorders that predominantly affect small vessels (such as capillaries, venules, arterioles, and small arteries) that are associated with antibodies against either one of 2 enzymes found in the cytoplasm of white blood cells known as neutrophils: myeloperoxidase (MPO) or serine proteinase 3 (PR3).¹

The major variants of ANCA vasculitis include:¹

- Granulomatosis with polyangiitis (GPA) (formerly known as Wegener's granulomatosis)
- Microscopic polyangiitis (MPA)
- Eosinophilic granulomatosis with polyangiitis (EGPA) (formerly known as Churg-Strauss syndrome)

The incidence, prevalence, and age of onset of each of the ANCA variants are summarized in Table 1. As will be discussed later in this article, the ANCA vasculitis subtypes are each associated with different subsets of disease manifestations. GPA and MPA have considerable overlaps in pathophysiology and clinical manifestations that have led them to be studied together in clinical trials. EGPA is the least frequent type of ANCA vasculitis. It is less well studied than either GPA or MPA, and its treatment is often inferred from MPA and GPA clinical studies or based on the results of uncontrolled clinic trials and observational studies.^{3,6}

Author Disclosures: *The authors report the following financial relationships: Curry L. Koenig, MD, MS, has been a consultant to ChemoCentryx, Inc; Irene von Hennigs, PharmD, is an employee of ChemoCentryx, Inc.*

Address correspondence to: curry.koenig@hsc.utah.edu

TABLE 1 COMPARISON OF THE 3 DIFFERENT TYPES OF ANCA VASCULITIS³

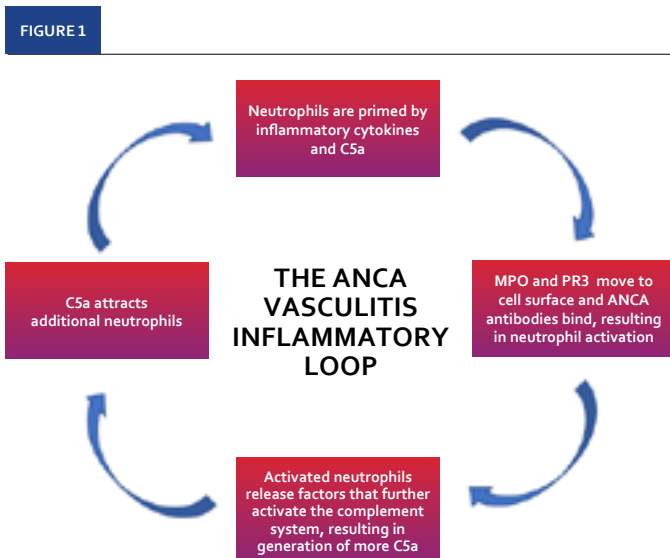
Feature	Granulomatosis with polyangiitis	Microscopic polyangiitis	Eosinophilic granulomatosis with polyangiitis
Incidence per 1 million person-years	0.4–11.9	0.5–24.0	0.5–2.3
Prevalence per 1 million persons	2.3–146.0	9.0–94.0	2.0–22.3
Typical age at onset, years	45–65	55–75	38–54
Male: female ratio	1:1	1:1	1:1

ANCA, antineutrophil cytoplasmic antibody.

WHAT IS THE PATHOPHYSIOLOGY OF ANCA-ASSOCIATED VASCULITIS?

The initial triggering event(s) that cause ANCA-associated vasculitis remain under intensive study. MPO and PR3—the enzymes in neutrophils that are the target of ANCAs—are normally sheltered from the immune system and are quickly neutralized after their release to prevent the formation of autoantibodies.^{3,7-10} In ANCA vasculitis, these proteins, which are normally “hidden” from the immune response, are detected by the immune system, resulting in the development of antibodies against them.

The inflammation associated with ANCA vasculitis begins when neutrophils are primed for activation by inflammatory cytokines, such as interleukin (IL)-1 and IL-18 that are produced in response to infection or another



ANCA, antineutrophil cytoplasmic antibodies; MPO, myeloperoxidase; PR3, serine proteinase 3.

event.¹¹ Neutrophil priming leads to the generation of C5a, a protein fragment that is part of the complement system that is normally involved in enhancing the ability of the immune system to clear microbes and damaged cells from the body. C5a exerts its activity through binding to its receptor, C5aR, on neutrophils. Once bound, C5a further primes the neutrophil and functions as a strong chemoattractant, recruiting more inflammatory cells to the site. At the same time, priming of neutrophils results in the movement of MPO and PR3 from the interior to the surface of neutrophils, allowing ANCA autoantibodies to bind (Figure 1).⁹

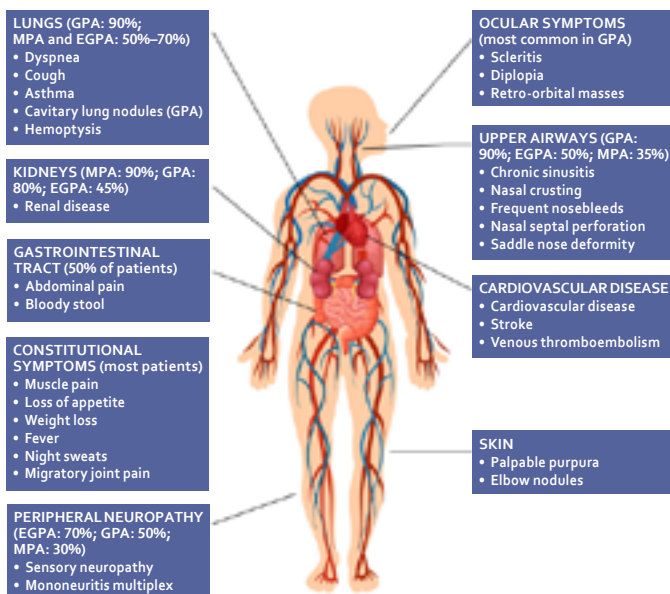
ANCA-activated neutrophils release additional factors that activate the complement system, resulting in the generation of more C5a that attracts and primes additional neutrophils, causing blood vessel inflammation. Activated neutrophils penetrate the walls of blood vessels and release enzymes and other substances that damage the endothelium, the lining of blood vessels.^{9,12} Chronically inflamed blood vessels can become stenotic or occluded, causing ischemia in downstream organs.

WHAT ARE THE CLINICAL MANIFESTATIONS OF ANCA VASCULITIS?

ANCA vasculitis is associated with a large number of clinical features that can make the diagnosis challenging, as clinical features overlap with numerous other disease states (Figure 2). The manifestations of ANCA vasculitis are truly systemic and can affect nearly every organ system, although the prevalence and precise clinical manifestations vary by subtype.

- **Constitutional symptoms:** Most patients with ANCA vasculitis often experience constitutional symptoms, such as muscle pain, loss of appetite and weight loss, fever, night sweats, and migratory joint pain.^{2,13} These constitutional symptoms may appear weeks or months before the development of specific organ involvement.¹³
- **Lung involvement:** The lower respiratory tract is involved in about 90% of patients with GPA and 50% to 70% of patients with MPA and EGPA.¹³ The clinical presentation of lung disease is variable, but patients may present with some combination of hemoptysis, shortness of breath, and cough. All patients with EGPA should have asthma.² The severity of lung disease can range from mild obstructive lung disease in EGPA to cavitary lung nodules or hemoptysis in patients with GPA. Bronchial inflammation is common in patients with GPA and EGPA, and alveolar hemorrhage can occur in all 3 diseases.²
- **Upper airway involvement:** The upper airways are most commonly affected in patients with GPA (90%); upper airway involvement is less common in patients with MPA (35%) and EGPA (50%).¹³ Upper airway disease is commonly characterized by chronic sinusitis, nasal crusting, and frequent nosebleeds in GPA. Ongoing inflammation in

FIGURE 2 THE ANCA VASCULITIS DISEASE MANIFESTATIONS^{3,13,18}



EGPA, eosinophilic granulomatosis with polyangiitis; GPA, granulomatosis with polyangiitis; MPA, microscopic polyangiitis.

GPA can cause nasal septal perforation and saddle nose deformity.^{14,15} Patients with EGPA may develop sinus polyps and paranasal sinusitis.

- **Kidney involvement:** The kidneys are involved in up to 90% of patients with MPA, 80% of those with GPA, and 45% of those with EGPA.¹³ Renal inflammation can result in rapid progression to end-stage renal disease requiring renal replacement therapy or transplant if not detected and treated early.^{16,17}
- **Cardiovascular disease:** Patients with ANCA vasculitis are at a 3-fold increased risk for cardiovascular disease, 8-fold increased risk for stroke, and 6-fold increased risk for venous thromboembolism compared with the general population.^{18,19} This increase in risk appears to be independent of other conventional cardiovascular risk factors, such as hypercholesterolemia and smoking.¹⁸ Patients with ANCA vasculitis can have an increased frequency of thromboembolic events.¹²
- **Peripheral neuropathy:** Vasculitis of the small arteries that supply the peripheral nerves results in peripheral neuropathy in up to 70% of patients with EGPA, 50% of patients with GPA, and 30% of patients with MPA. Patients may present with sensory polyneuropathy or mononeuritis multiplex.^{3,13,20}
- **Skin involvement:** Skin involvement is common; skin manifestations most often include purpura in the lower extremities or nodules on the elbows, although other cutaneous manifestations may occur.^{13,21}

- **Gastrointestinal involvement:** At least half of patients with ANCA vasculitis have abdominal pain or bloody stools due to vasculitis of abdominal vessels.²²
- **Ocular symptoms:** Eye pain due to scleritis or diplopia as a result of a retro-orbital mass is seen in about 20% of patients and is most common in patients with GPA.^{2,23}

The broad range of organ systems targeted by ANCA vasculitis often requires a multidisciplinary approach to care; collaboration with otolaryngologists, pulmonologists, and nephrologists is critical to provide the best care for these patients. These patients are often complex and difficult to manage, both due to disease manifestations and the multiple medications required for managing the spectrum of disease.

HOW IS ANCA VASCULITIS DIAGNOSED?

ANCA vasculitis is diagnosed clinically, with support from blood and urine tests for the presence of ANCA, radiographic imaging, and biopsy of affected organs.² Clinicians should suspect ANCA vasculitis if there is multisystem involvement, defined as the presence of 2 or more of the signs and symptoms summarized above.² Patients should be tested for ANCA; however, a negative test does not exclude the disease.² Imaging findings of destructive sinus disease, lung nodules, or lung opacities may be used by clinicians to support a diagnosis.⁶

HOW IS ANCA VASCULITIS CURRENTLY TREATED?

Treatment of ANCA vasculitis requires the use of glucocorticoids in combination with a conventional synthetic disease-modifying antirheumatic drug or biologic agent. Toxicity due to treatment is a common problem. In fact, treatment-related adverse events, as opposed to active vasculitis, are currently the major cause of death during the initial stages of treatment for ANCA vasculitis.¹⁶

Treatment of patients with severe ANCA vasculitis is divided into 2 stages: an initial induction phase that aims to suppress inflammation as rapidly as possible, followed by a maintenance of remission phase.

Remission Induction Phase

For patients with severe disease, remission induction involves the combination of high-dose glucocorticoids with either of the following:

- Cyclophosphamide, an alkylating agent that is commonly used to treat certain types of cancer. Cyclophosphamide has a broad range of toxicities, including bone marrow suppression, cardiac and gonadal toxicity, inflammation and bleeding of the urinary bladder, and long-term risk for urologic or hematologic malignancies.²⁴ Use of cyclophosphamide for more than 3 to 6 months is generally not recommended because of these toxicities.⁶
- The monoclonal anti-CD20 agent rituximab acts by

depleting pre-B and mature B cells, the precursors of antibody-producing plasma cells.²⁵ Rituximab is currently the only agent approved for the management of GPA and MPA in combination with glucocorticoids.²⁵ Rituximab has fewer toxicities than cyclophosphamide and may be the preferred agent for particular patients.³

Glucocorticoids remain the cornerstone of therapy for ANCA vasculitis and are highly effective in the management of a broad range of inflammatory and autoimmune disorders. Intravenous methylprednisolone may be administered at dosages ranging from 500 to 1000 mg daily for 3 days, followed by conversion to oral prednisone 1 mg/kg/d for up to 2 to 4 weeks in patients with critical organ involvement. Thereafter, the dosage is tapered over several weeks to months, with either complete discontinuation or maintenance at low doses of 5 mg/d or less.²⁴

Regimens that reduce glucocorticoid dosage or replace them altogether are continuously being sought after because of the high incidence of significant toxicities associated with these agents, including an increased risk for infection, diabetes mellitus, osteoporosis and bone fracture, hypertension, cataracts, gastrointestinal bleeding, and others. These agents are also commonly associated with weight gain, sleep disturbances, lipid abnormalities, and serious neuropsychiatric disturbances.^{26,27} Patients who are receiving chronic glucocorticoids must be monitored closely for the development of treatment-related toxicities, and additional medications may be required to avoid some toxicities. Recent evidence suggests that the dosage of glucocorticoids can be more rapidly tapered than has been the standard in the past; rapid-taper regimens reduce the risk for serious infections by nearly one-third.²⁸ Alternative or additional drugs that can further reduce glucocorticoid burden in patients with ANCA vasculitis are desirable.

Plasma exchange may be a rapid way to remove pathogenic ANCA and other proinflammatory proteins without the risks of systemic therapies. Older studies suggested that it may improve renal survival in patients with ANCA vasculitis by reducing progression to end-stage renal disease when compared with intravenous glucocorticoids.^{6,29} However, a recent study found that it may have no impact on death or the development of end-stage renal disease.²⁸

Patients with less-severe disease may be treated with alternative immunosuppressive agents that may have a lower adverse effect burden than cyclophosphamide.⁶ Methotrexate and mycophenolate mofetil, both in combination with glucocorticoids, are as effective as cyclophosphamide-based regimens for remission induction in patients with nonsevere disease.^{3,30,31} However, these agents may be associated with less-effective disease control and higher relapse rates than the standard regimens used in severe disease.^{31,32}

Remission Maintenance Phase

Remission induction is followed by a maintenance phase. Azathioprine, rituximab, methotrexate, or mycophenolate mofetil, with or without low-dose glucocorticoids, are commonly used at this stage. Glucocorticoids should be tapered to the lowest effective dose, which is usually 5 mg/d or less.⁶ Azathioprine may be a more effective maintenance therapy than mycophenolate mofetil.³³

Recent evidence suggests that rituximab given every 4 to 6 months for 18 months is associated with lower relapse rates than azathioprine.³⁴ Recent guidelines recommend rituximab for remission maintenance in most patients who receive a rituximab-based regimen for remission induction; it can also be considered as maintenance therapy for patients who receive cyclophosphamide-based remission induction therapy.³⁵

WHAT FUTURE TREATMENTS SHOULD WE KEEP AN EYE ON?

When diagnosed early and treated promptly, current therapies for ANCA vasculitis are successful in reducing or preventing target organ damage. However, there remains a need for alternative therapeutics. In particular, patients with ANCA vasculitis have a 9-fold increased risk of mortality in the first year of treatment compared with healthy individuals, both as a result of inadequate suppression of disease progression and treatment-related adverse events.^{16,36} Further, even with appropriate treatment with current regimens, more than one-third of patients progress to end-stage renal disease within 5 years of diagnosis as a result of inadequately controlled disease.^{17,37-39}

The toxicities of glucocorticoids remain an important source of morbidity for patients. The impact of long-term treatment with glucocorticoids was evaluated using data from 6 studies of treated ANCA vasculitis enrolling 629 patients. In this study, toxicities related to glucocorticoid treatment, including hypertension (41%), osteoporosis (14.1%), and diabetes (10.4%), were seen in most patients⁴⁰

It is clear that current regimens have substantial efficacy but also safety limitations. Glucocorticoid-sparing treatment regimens remain an important unmet need. Several new therapies are in late-stage development for ANCA vasculitis, including abatacept and avacopan. Only avacopan, an orally administered inhibitor of complement C5a receptor, has completed a Phase 3 trial.⁴¹⁻⁴³ The selective costimulation modulator abatacept has shown promising results in small studies so far.⁴⁴ Other therapies are in early-stage development.

Avacopan

Avacopan is a monoclonal antibody that blocks the C5a receptor.^{43,45} Animal studies have shown that blocking this receptor was effective in reducing MPO antibody-induced renal damage and in blocking C5a-induced white blood cell accumulation and adhesion to the blood vessel walls.^{43,45}

Avacopan has been evaluated in a number of clinical studies. Most recently, a phase 3 trial evaluated the efficacy of avacopan in patients with either newly diagnosed or relapsing GPA or MPA that required treatment with cyclophosphamide or rituximab.⁴¹ Patients were randomized to receive oral avacopan 30 mg twice daily or oral prednisone on a tapering schedule. All patients received either cyclophosphamide (followed by azathioprine) or rituximab. Patients were assessed at week 26 for remission (with no glucocorticoid use during the 4 weeks before week 26) using the Birmingham Vasculitis Activity Score.⁴¹

The study included 331 patients, about two-thirds of whom were newly diagnosed and one-third of whom had relapsed disease. Remission at 26 weeks was seen in similar percentages of the avacopan group (72.3%) and prednisone group (70.1%), indicating that avacopan was noninferior to prednisone. Sustained remission, which was defined as remission at both weeks 26 and 52 with no glucocorticoids during the 4 weeks before week 52, was superior and seen in significantly more patients in the avacopan group (65.7%) compared with the prednisone group (54.9%) ($P < 0.001$ for noninferiority; $P = 0.007$ for superiority). Relapses were more common with prednisone (21.0%) than with avacopan (10.1%). Avacopan also appeared to have a beneficial effect on renal function relative to prednisone, with an estimated glomerular filtration rate change from baseline of 7.3 mL/min/1.73 m² in the avacopan group vs 4.1 mL/min/1.73 m² in the prednisone group (difference 3.2 mL/min/1.73 m²; 95% CI: 0.3-6.1).⁴¹ Among patients with stage 4 kidney disease, the mean change at week 52 was 13.7 mL/min/1.73 m² in the avacopan group and 8.2 mL/min/1.73 m² in the prednisone group (difference 5.6 mL/min/1.73 m²; 95% CI: 1.7-9.5).⁴¹

Avacopan reduced the need for glucocorticoid by nearly two-thirds. The incidence of adverse events potentially related to glucocorticoids was 66.3% with avacopan and 80.5% in the prednisone group. Serious adverse events, which most commonly consisted of a worsening of vasculitis, occurred in 42% of avacopan patients and 45% of prednisone patients.⁴¹

Abatacept

Abatacept is an intravenously or subcutaneously administered fusion protein that blocks the activation of T cells, which are implicated in the pathogenesis of many autoimmune diseases. It is currently approved for adult rheumatoid arthritis, juvenile idiopathic arthritis, and adult psoriatic arthritis.⁴⁶

Abatacept has only been evaluated in a small 20-patient trial in patients with a nonsevere relapse of GPA, although a phase 3 trial is ongoing.^{44,47} Patients received 3 doses of intravenous abatacept during the first month, followed by monthly treatment for at least 6 months. Patients received up to 30 mg/d of prednisone at study entry, which was subsequently tapered.

Among the 20 patients enrolled in the study, disease improvement occurred in 90% and remissions were achieved in

80% of patients at a median of 1.9 months. Remissions lasted a median of 14.4 months. Seventy-three percent of patients who received prednisone tapered completely off glucocorticoids.⁴⁴ A total of 6 patients (30%) experienced increased disease activity while on abatacept.

CONCLUSIONS

The diagnosis, initial treatment, and long-term management of ANCA vasculitis is complex and requires coordination across multiple specialties to address the broad range of clinical manifestations that characterize these diseases. When diagnosed and treated promptly, treatment can reduce morbidity and be lifesaving. However, clear gaps remain in the management of ANCA vasculitis in both more complete suppression of disease progression and reducing treatment-related toxicities. To address the latter of these 2 limitations, many clinical trials have been conducted to reduce exposure to or to eliminate the need for cyclophosphamide and glucocorticoids, both of which are associated with significant treatment toxicities. Clinical studies suggest that rituximab may be used in place of cyclophosphamide, and in some cases may be the preferred agent. However, there remains a need to reduce the toxicities associated with corticosteroids.

Activation of the complement system appears to play an important role in initiating and exacerbating the inflammatory cascade that characterizes ANCA vasculitis. These findings have led to the development of agents that specifically inhibit the complement system by targeting C5a/C5aR. Phase 3 clinical trial data for avacopan, a novel small-molecule orally administered C5aR antagonist, suggest that it may have a role in eliminating or reducing the dose of glucocorticoids when given in combination with rituximab or cyclophosphamide. ■

REFERENCES

- Jennette JC, Falk RJ, Bacon PA, et al. 2012 revised International Chapel Hill Consensus Conference Nomenclature of Vasculitides. *Arthritis Rheum.* 2013;65(1):1-11.
- Hunter RW, Welsh N, Farrah TE, Gallacher PJ, Dhaun N. ANCA associated vasculitis. *BMJ.* 2020;369:m1070.
- Kitching AR, Anders HJ, Basu N, et al. ANCA-associated vasculitis. *Nat Rev Dis Primers.* 2020;6(1):71.
- Pearce FA, Hubbard RB, Grainge MJ, Watts RA, Abhishek A, Lanyon PC. Can granulomatosis with polyangiitis be diagnosed earlier in primary care? A case-control study. *QJM.* 2018;111(1):39-45.
- Fauci AS, Haynes BF, Katz P, Wolff SM. Wegener's granulomatosis: prospective clinical and therapeutic experience with 85 patients for 21 years. *Ann Intern Med.* 1983;98(1):76-85.
- Yates M, Watts RA, Bajema IM, et al. EULAR/ERA-EDTA recommendations for the management of ANCA-associated vasculitis. *Ann Rheum Dis.* 2016;75(9):1583-1594.
- Aratani Y. Myeloperoxidase: Its role for host defense, inflammation, and neutrophil function. *Arch Biochem Biophys.* 2018;640:47-52.

8. Sugawara S. Immune functions of proteinase 3. *Crit Rev Immunol*. 2005;25(5):343-360.
9. Nakazawa D, Masuda S, Tomaru U, Ishizu A. Pathogenesis and therapeutic interventions for ANCA-associated vasculitis. *Nat Rev Rheumatol*. 2019;15(2):91-101.
10. Hutton HL, Holdsworth SR, Kitching AR. ANCA-associated vasculitis: pathogenesis, models, and preclinical testing. *Semin Nephrol*. 2017;37(5):418-435.
11. Al-Hussain T, Hussein MH, Conca W, Al Mana H, Akhtar M. Pathophysiology of ANCA-associated vasculitis. *Adv Anat Pathol*. 2017;24(4):226-234.
12. Chen M, Jayne DRW, Zhao MH. Complement in ANCA-associated vasculitis: mechanisms and implications for management. *Nat Rev Nephrol*. 2017;13(6):359-367.
13. Rowaiye OO, Kuzstal M, Klinger M. The kidneys and ANCA-associated vasculitis: from pathogenesis to diagnosis. *Clin Kidney J*. 2015;8(3):343-350.
14. Wallace ZS, Miloslavsky EM. Management of ANCA associated vasculitis. *BMJ*. 2020;368:m421.
15. Yates M, Watts R. ANCA-associated vasculitis. *Clin Med (Lond)*. 2017;17(1):60-64.
16. Little MA, Nightingale P, Verburgh CA, et al. Early mortality in systemic vasculitis: relative contribution of adverse events and active vasculitis. *Ann Rheum Dis*. 2010;69(6):1036-1043.
17. Corral-Gudino L, Borao-Cengotita-Bengoa M, Del Pino-Montes J, Lerma-Marquez JL. Overall survival, renal survival and relapse in patients with microscopic polyangiitis: a systematic review of current evidence. *Rheumatology (Oxford)*. 2011;50(8):1414-1423.
18. Berti A, Matteson EL, Crowson CS, Specks U, Cornec D. Risk of cardiovascular disease and venous thromboembolism among patients with incident ANCA-associated vasculitis: a 20-year population-based cohort study. *Mayo Clin Proc*. 2018;93(5):597-606.
19. Kronbichler A, Leierer J, Gauckler P, Shin JI. Comorbidities in ANCA-associated vasculitis. *Rheumatology (Oxford)*. 2020;59(Suppl 3):iii79-iii83.
20. Suppiah R, Hadden RD, Batra R, et al. Peripheral neuropathy in ANCA-associated vasculitis: outcomes from the European Vasculitis Study Group trials. *Rheumatology (Oxford)*. 2011;50(12):2214-2222.
21. Micheletti RG, Chiesa Fuxench Z, Craven A, et al. Cutaneous manifestations of antineutrophil cytoplasmic antibody-associated vasculitis. *Arthritis Rheumatol*. 2020;72(10):1741-1747.
22. Franco DL, Ruff K, Mertz L, Lam-Himlin DM, Heigh R. Eosinophilic granulomatosis with polyangiitis and diffuse gastrointestinal involvement. *Case Rep Gastroenterol*. 2014;8(3):329-336.
23. Schmidt J, Pulido JS, Matteson EL. Ocular manifestations of systemic disease: antineutrophil cytoplasmic antibody-associated vasculitis. *Curr Opin Ophthalmol*. 2011;22(6):489-495.
24. Emadi A, Jones RJ, Brodsky RA. Cyclophosphamide and cancer: golden anniversary. *Nat Rev Clin Oncol*. 2009;6(11):638-647.
25. Rituxin (rituximab) [prescribing information]. South San Francisco, CA: Genentech, Inc. 2020.
26. McDonough AK, Curtis JR, Saag KG. The epidemiology of glucocorticoid-associated adverse events. *Curr Opin Rheumatol*. 2008;20(2):131-137.
27. Fardet L, Flahault A, Kettaneh A, et al. Corticosteroid-induced clinical adverse events: frequency, risk factors and patient's opinion. *Br J Dermatol*. 2007;157(1):142-148.
28. Walsh M, Merkel PA, Peh CA, et al. Plasma exchange and glucocorticoids in severe ANCA-associated vasculitis. *N Engl J Med*. 2020;382(7):622-631.
29. Jayne DR, Gaskin G, Rasmussen N, et al. Randomized trial of plasma exchange or high-dosage methylprednisolone as adjunctive therapy for severe renal vasculitis. *J Am Soc Nephrol*. 2007;18(7):2180-2188.
30. De Groot K, Rasmussen N, Bacon PA, et al. Randomized trial of cyclophosphamide versus methotrexate for induction of remission in early systemic antineutrophil cytoplasmic antibody-associated vasculitis. *Arthritis Rheum*. 2005;52(8):2461-2469.
31. Jones RB, Hiemstra TF, Ballarin J, et al. Mycophenolate mofetil versus cyclophosphamide for remission induction in ANCA-associated vasculitis: a randomised, non-inferiority trial. *Ann Rheum Dis*. 2019;78(3):399-405.
32. Faurschou M, Westman K, Rasmussen N, et al. Brief Report: long-term outcome of a randomized clinical trial comparing methotrexate to cyclophosphamide for remission induction in early systemic antineutrophil cytoplasmic antibody-associated vasculitis. *Arthritis Rheum*. 2012;64(10):3472-3477.
33. Hiemstra TF, Walsh M, Mahr A, et al. Mycophenolate mofetil vs azathioprine for remission maintenance in antineutrophil cytoplasmic antibody-associated vasculitis: a randomized controlled trial. *JAMA*. 2010;304(21):2381-2388.
34. Guillevin L, Pagnoux C, Karras A, et al. Rituximab versus azathioprine for maintenance in ANCA-associated vasculitis. *N Engl J Med*. 2014;371(19):1771-1780.
35. Tieu J, Smith R, Basu N, et al. Rituximab for maintenance of remission in ANCA-associated vasculitis: expert consensus guidelines. *Rheumatology (Oxford)*. 2020;59(4):e24-e32.
36. Luqmani R, Suppiah R, Edwards CJ, et al. Mortality in Wegener's granulomatosis: a bimodal pattern. *Rheumatology (Oxford)*. 2011;50(4):697-702.
37. Koldingsnes W, Nossent H. Predictors of survival and organ damage in Wegener's granulomatosis. *Rheumatology (Oxford)*. 2002;41(5):572-581.
38. Takala JH, Kautiainen H, Finne P, Leirisalo-Repo M. Wegener's granulomatosis in Finland in 1981-2000: risk of dialysis-dependent renal disease. *Scand J Rheumatol*. 2011;40(4):283-288.
39. Mohammad AJ, Segelmark M. A population-based study showing better renal prognosis for proteinase 3 antineutrophil cytoplasmic antibody (ANCA)-associated nephritis versus myeloperoxidase ANCA-associated nephritis. *J Rheumatol*. 2014;41(7):1366-1373.
40. Robson J, Doll H, Suppiah R, et al. Damage in the anca-associated vasculitides: long-term data from the European vasculitis study group (EUVAS) therapeutic trials. *Ann Rheum Dis*. 2015;74(1):177-184.
41. Jayne DRW, Merkel PA, Schall TJ, Bekker P, Group AS. Avacopan for the treatment of ANCA-associated vasculitis. *N Engl J Med*. 2021;384(7):599-609.
42. Trivioli G, Vaglio A. The rise of complement in ANCA-associated vasculitis: from marginal player to target of modern therapy. *Clin Exp Immunol*. 2020;202(3):403-406.
43. Xiao H, Dairaghi DJ, Powers JP, et al. C5a receptor (CD88) blockade protects against MPO-ANCA GN. *J Am Soc Nephrol*. 2014;25(2):225-231.
44. Langford CA, Monach PA, Specks U, et al. An open-label trial of abatacept (CTLA4-IG) in non-severe relapsing granulomatosis with polyangiitis (Wegener's). *Ann Rheum Dis*. 2014;73(7):1376-1379.
45. Bekker P, Dairaghi D, Seitz L, et al. Characterization of pharmacologic and pharmacokinetic properties of CCX168, a potent and selective orally administered complement 5a receptor inhibitor, based on preclinical evaluation and randomized phase 1 clinical study. *PLoS One*. 2016;11(10):e0164646.
46. Orenca (abatacept) [prescribing information]. Princeton, NJ: Bristol Myers Squibb. 2020.
47. ClinicalTrials.gov. Abatacept for the treatment of relapsing, non-severe, granulomatosis with polyangiitis (Wegener's) (NCT02108860). <https://www.clinicaltrials.gov/ct2/show/NCT02108860>. Accessed February 26, 2021.

Take this exam online >

Take the test online and then immediately print your certificate after successfully completing the test. Or print, complete and mail the exam on the next page.
Exam expires September 15, 2022.

This exam is FREE to all.

[Click here to join ACCM](#) and get access to more CEs—up to 24 per year!

The Spectrum of Antineutrophil Cytoplasmic Antibody (ANCA)-Associated Vasculitis: DISEASE FUNDAMENTALS AND MANAGEMENT PATHWAYS

Questions

- ANCA vasculitis is a group of rare life-threatening autoimmune disorders that are marked by a necrotizing inflammatory process predominantly affecting small- and medium-sized blood vessels.
 - True
 - False
- ANCA vasculitis is a systemic disease that can affect which of the following body systems?
 - Respiratory
 - Renal
 - Cardiovascular
 - All of the above
- Left untreated, what percentage of patients with ANCA vasculitis will survive more than 2 years?
 - 5%
 - 7.5%
 - 10%
 - 12.5%
- Optimal management of ANCA vasculitis requires coordinated multidisciplinary care because of the breadth of organ systems involved and the complexity of treatment. Multidisciplinary care should include which of the following specialists?
 - Otolaryngologists
 - Pulmonologists
 - Nephrologists
 - All of the above
- The enzymes in neutrophils that are targets of ANCA vasculitis are myeloperoxidase (MPO) and serine proteinase 3 (PR3).
 - True
 - False
- Each of the three different types of ANCA vasculitis can occur anytime in a person's life span.
 - True
 - False
- Priming neutrophils play an important role allowing ANCA autoantibodies to bind.
 - True
 - False
- The diagnosis of ANCA vasculitis is challenging because clinical features overlap numerous other diseases.
 - True
 - False
- The prevalence and precise clinical manifestations of ANCA vasculitis do not vary by subtype.
 - True
 - False
- ANCA vasculitis is diagnosed with support from:
 - Blood and urine tests for presence of ANCA
 - Radiographic imaging
 - Biopsy of affected organ(s)
 - All of the above
- Treatment of ANCA vasculitis requires the use of glucocorticoids and a conventional synthetic disease-modifying antirheumatic drug or biologic agent.
 - True
 - False
- Glucocorticoid usage has significant toxicities including:
 - Increased risk of infection(s)
 - Increased risk of diabetes mellitus
 - Increased risk of hypertension
 - All of the above
- Which of the following are commonly used with or without low-dose glucocorticoids in the maintenance phase of ANCA vasculitis?
 - Azathioprine
 - Rituximab
 - Methotrexate
 - Mycophenolate mofetil
 - All of the above
- In their first year of treatment, what is the increased risk of mortality in patients with ANCA vasculitis compared with healthy individuals?
 - 5-fold
 - 7-fold
 - 9-fold
 - 11-fold
- Even with appropriate treatment, how many patients with ANCA vasculitis will progress to end-stage renal disease within 5 years of diagnosis as a result of inadequately controlled disease?
 - >20%
 - >25%
 - >33%
 - None of the above
- Two late-stage glucocorticoid-sparing treatment regimens in development for ANCA vasculitis include avacopan and abatacept.
 - True
 - False

CE exams may be taken online! Click the link on the previous page to take the test online and then immediately print your certificate after successfully completing the test. Or print, complete and mail this answer page to the address listed below. Exam expires September 15, 2022.

The Spectrum of Antineutrophil Cytoplasmic Antibody (ANCA)-Associated Vasculitis: DISEASE FUNDAMENTALS AND MANAGEMENT PATHWAYS

Objectives:

September 2021

1. Define ANCA-associated vasculitis. _____
2. Describe the pathophysiology of ANCA vasculitis. _____
3. State six clinical manifestations of ANCA vasculitis. _____
4. State two treatment options for ANCA vasculitis. _____

Please indicate your answer to the exam questions on the preceding page by filling in the letter:

1. ____ 2. ____ 3. ____ 4. ____ 5. ____ 6. ____ 7. ____ 8. ____ 9. ____ 10. ____

Continuing Education Program Evaluation:

Please indicate your rating by circling the appropriate number using a scale of 1 (low) to 5 (high).

- | | | | | | |
|--|---|---|---|---|---|
| 1. The objectives were met. | 1 | 2 | 3 | 4 | 5 |
| 2. The article was clear and well organized. | 1 | 2 | 3 | 4 | 5 |
| 3. The topic was both relevant and interesting to me. | 1 | 2 | 3 | 4 | 5 |
| 4. The amount and depth of the material was adequate. | 1 | 2 | 3 | 4 | 5 |
| 5. The quality and amount of the graphics were effective. | 1 | 2 | 3 | 4 | 5 |
| 6. I would recommend this article. | 1 | 2 | 3 | 4 | 5 |
| 7. This has been an effective way to present continuing education. | 1 | 2 | 3 | 4 | 5 |
| 8. Additional comments: _____ | | | | | |

Please print:

Certificant's Name: _____ CCM ID# _____
 Email Address: _____ CDMS ID# _____
 Mailing Address: _____ RN ID# _____
 _____ ACCM Membership# _____
 _____ ACCM Expiration Date: _____

___ CE contact hours applied for: CCM RN CDM

*CE exams cannot be processed without above information.

This educational manuscript has been approved for 2 contact hours of nursing credit by the California Board of Registered Nursing. To receive credit for either exam, you must score 80% or above. Exam expires September 15, 2022.

Please note: Exam may be taken online at www.academyCCM.org/ce or click the link found in this supplement, take the exam, and immediately print your certificate after successfully completing the test. Mailed exams should be sent to: Academy of Certified Case Managers, 1574 Coburg Road #225, Eugene, Oregon 97401. Please allow 4 to 6 weeks for processing of mailed exams.

This CE exam is protected by US Copyright law. You are permitted to make one copy for the purpose of exam submission. Multiple copies are not permitted.

If you are not an ACCM member and wish to become one, please [click here](#).